

Difficulties and complications in treating a case of congenital pseudarthrosis of the tibia during humanitarian missions

CHL
KANNIERKLINIK

Rene Castro Gayito Adagba
Pierre Louis Docquier
Robert Elbaum
Claire Gauthier
Romeo Haoudou
Fabian Mougondo
Jerry Kieffer



Chaîne de l'Espoir Luxembourg
CHAÎNE DE L'ESPOIR - BELGIQUE
KETTEN VAN HOOP - BELGIË

1

Difficulties and complications in treating a case of congenital pseudarthrosis of the tibia during humanitarian missions

CHL
KANNIERKLINIK

Anselme, born 30.12.2008

04.2014 Benin: resection of pseudarthrosis, iliac crest graft, flexible intramedullary nailing and Hoffmann external fixator
10.2014 Benin: removal of external fixator, iliac crest graft, Taylor spatial frame
02.2015 Benin: removal of TSF and plaster cast
10.2015 Benin: removal of FIN, iliac crest graft, Taylor spatial frame
02.2016 Benin: removal of TSF and plaster cast, followed 3 month later by an orthosis
11. 2017 Luxembourg: resection of pseudarthrosis, intramedullary nailing with Bailey telescoping intramedullary nail, iliac crest and periosteum graft, BMP, ilizarov external fixator with compression and proximal 11 cm lengthening
01.2019 Luxembourg: removal of ilizarov fixator, graft augmentation with iliac crest bone and BMP, full weight bearing with Sarmiento type orthosis



2

Difficulties and complications in treating a case of congenital pseudarthrosis of the tibia during humanitarian missions

CHL
KANNIERKLINIK



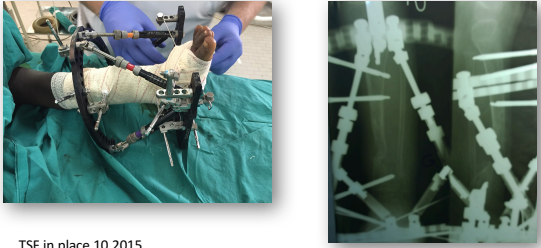
clinical image and x-ray before first surgery 04.2014
clinical image and x-ray before third surgery 10.2015

Chaîne de l'Espoir Luxembourg
CHAÎNE DE L'ESPOIR - BELGIQUE
KETTEN VAN HOOP - BELGIË

3

Difficulties and complications in treating a case of congenital pseudarthrosis of the tibia during humanitarian missions

CHL
KANNIERKLINIK



TSF in place 10.2015
1 month post op

Chaîne de l'Espoir Luxembourg
CHAÎNE DE L'ESPOIR - BELGIQUE
KETTEN VAN HOOP - BELGIË

4

Difficulties and complications in treating a case of congenital pseudarthrosis of the tibia during humanitarian missions

CHL
KANNIERKLINIK




Clinical image after removal of TSF 02.2016

Chaîne de l'Espoir Luxembourg
CHAÎNE DE L'ESPOIR - BELGIQUE
KETTEN VAN HOOP - BELGIË

5

Difficulties and complications in treating a case of congenital pseudarthrosis of the tibia during humanitarian missions

CHL
KANNIERKLINIK



x-rays on arrival in Luxembourg 11.2017
LLD 11 cm

Chaîne de l'Espoir Luxembourg
CHAÎNE DE L'ESPOIR - BELGIQUE
KETTEN VAN HOOP - BELGIË

6

Difficulties and complications in treating a case of congenital pseudarthrosis of the tibia during humanitarian missions

CHL
KANNIERKLINIK

PALEY protocol of CPT treatment

Logo: Chaîne de l'Espoir Luxembourg, CHL KANNIERKLINIK, CHAÎNE DE L'ESPOIR - BELGIË, NIET VAN HOOP - BELGIË

7

Difficulties and complications in treating a case of congenital pseudarthrosis of the tibia during humanitarian missions

CHL
KANNIERKLINIK

Logo: Chaîne de l'Espoir Luxembourg, CHL KANNIERKLINIK, CHAÎNE DE L'ESPOIR - BELGIË, NIET VAN HOOP - BELGIË

8

Difficulties and complications in treating a case of congenital pseudarthrosis of the tibia during humanitarian missions

CHL
KANNIERKLINIK

Logo: Chaîne de l'Espoir Luxembourg, CHL KANNIERKLINIK, CHAÎNE DE L'ESPOIR - BELGIË, NIET VAN HOOP - BELGIË

9

Difficulties and complications in treating a case of congenital pseudarthrosis of the tibia during humanitarian missions

CHL
KANNIERKLINIK

Logo: Chaîne de l'Espoir Luxembourg, CHL KANNIERKLINIK, CHAÎNE DE L'ESPOIR - BELGIË, NIET VAN HOOP - BELGIË

10

Difficulties and complications in treating a case of congenital pseudarthrosis of the tibia during humanitarian missions

CHL
KANNIERKLINIK

Complications:

- wound infection at 2 weeks post op
- distal ipsilateral femur fracture 01.2018

Logo: Chaîne de l'Espoir Luxembourg, CHL KANNIERKLINIK, CHAÎNE DE L'ESPOIR - BELGIË, NIET VAN HOOP - BELGIË

11

Difficulties and complications in treating a case of congenital pseudarthrosis of the tibia during humanitarian missions

CHL
KANNIERKLINIK

Status after completion of lengthening and return to Benin

Logo: Chaîne de l'Espoir Luxembourg, CHL KANNIERKLINIK, CHAÎNE DE L'ESPOIR - BELGIË, NIET VAN HOOP - BELGIË

12

Difficulties and complications in treating a case of congenital pseudarthrosis of the tibia during humanitarian missions

CHL
KANNIERKLINIK

On return to Luxembourg
01.2019:
no weight bearing
since 05.2018 !

13

Difficulties and complications in treating a case of congenital pseudarthrosis of the tibia during humanitarian missions

CHL
KANNIERKLINIK

03.2019:
2 month after
graft augmentation
and weight bearing
with orthosis

14

Difficulties and complications in treating a case of congenital pseudarthrosis of the tibia during humanitarian missions

CHL
KANNIERKLINIK

work still in progress
open to discussion

Thank you

15