

25 april 2019, Oostende



# Complications in AC joint surgery

Gert Van den Bogaert  
*Orthopedisch chirurg  
schouderpathologie*

25 april 2019, Oostende

# Complications in AC joint surgery

Gert Van den Bogaert  
*Orthopedisch chirurg  
schouderpathologie*

## The "AC-joint enigma"

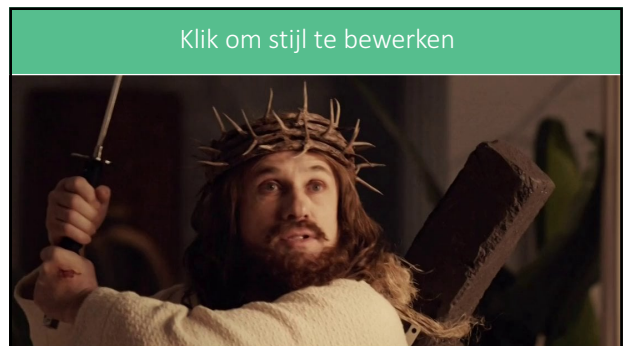
- 1 The essence of the lesion
- 2 Failure of existing AC joint reconstruction methods
- 3 A new concept?

## The "AC-joint enigma"

- 1 The essence of the lesion
  - ▶ The naked picture
  - ▶ The full house
- 2 Failure of existing AC joint reconstruction methods
- 3 A new concept?

## The "AC-joint enigma"

- 1 The essence of the lesion
  - ▶ The naked picture
  - ▶ The full house
- 2 Failure of existing AC joint reconstruction methods
- 3 A new concept?



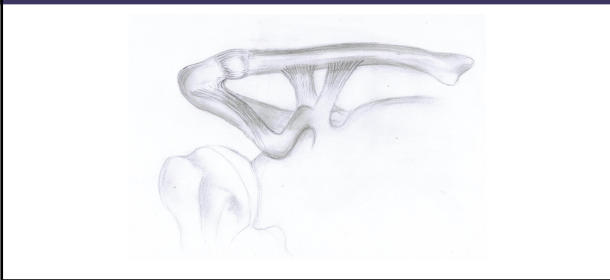
The full house



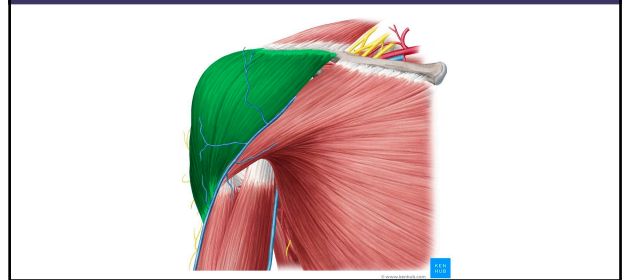
The full house



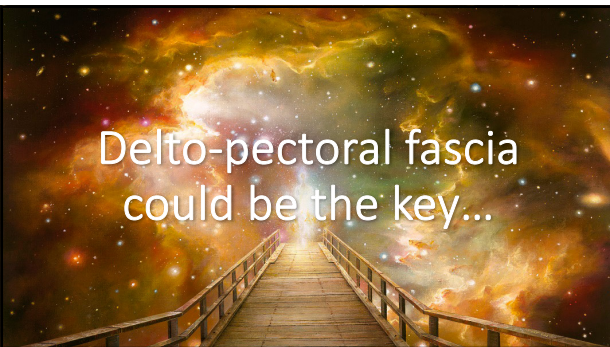
The naked picture



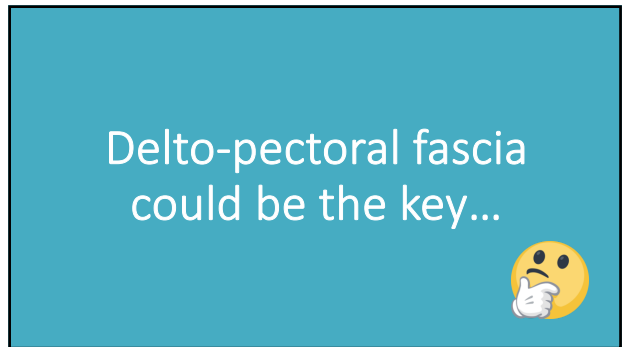
The full house



Delto-pectoral fascia  
could be the key...



Delto-pectoral fascia  
could be the key...



Delto-pectoral fascia  
could be the key...



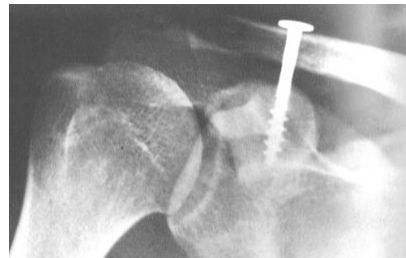
### The "AC-joint enigma"

- 1 The essence of the lesion
- 2 Failure of existing AC joint reconstruction methods
  - ▶ Fixation too rigid
  - ▶ Fixation too weak
- 3 A new concept?

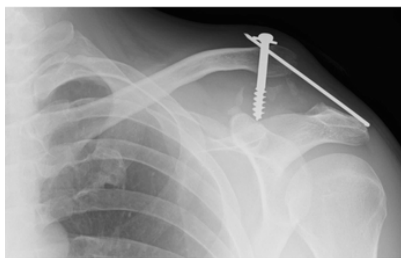
### The "AC-joint enigma"

- 1 The essence of the lesion
- 2 Failure of existing AC joint reconstruction methods
  - ▶ Fixation too rigid
  - ▶ Fixation too weak
- 3 A new concept?

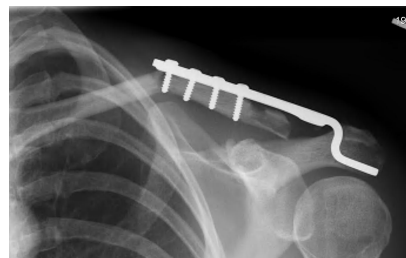
### Fixation too rigid



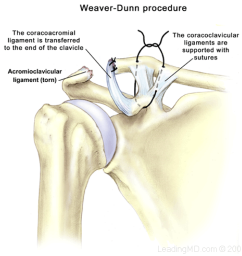
### Fixation too rigid



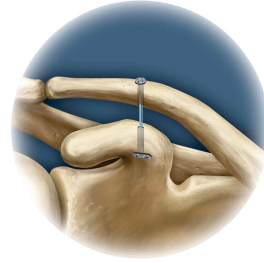
### Fixation too rigid



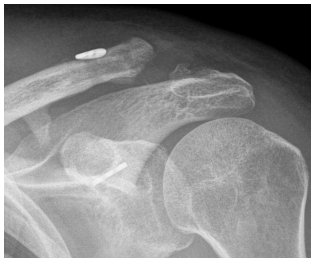Fixation too weak



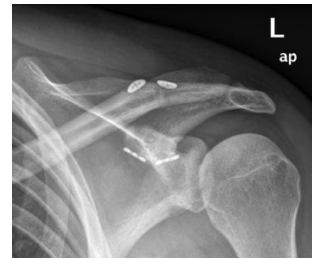
Fixation too weak



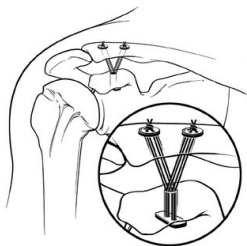
Fixation too weak



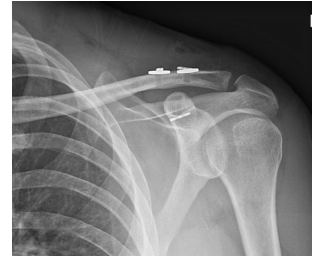
Fixation too weak



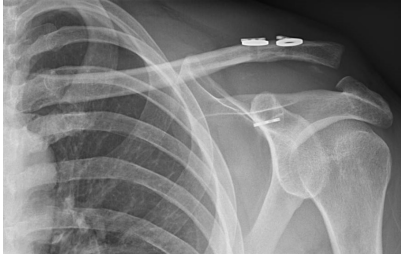
Fixation too weak



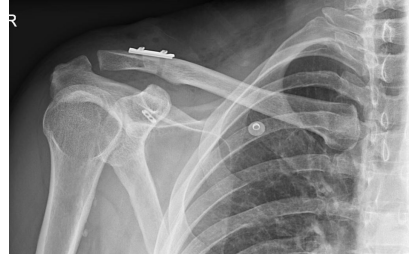
Fixation too weak



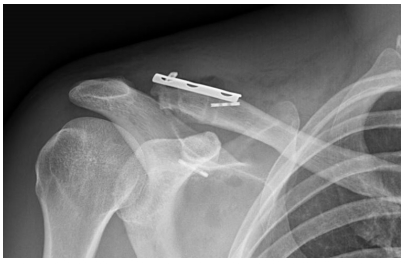Fixation too weak



Fixation too weak



Fixation too weak



### The "AC-joint enigma"

- 1 The essence of the lesion
- 2 Failure of existing AC joint reconstruction methods
- 3 A new concept?

SACS®

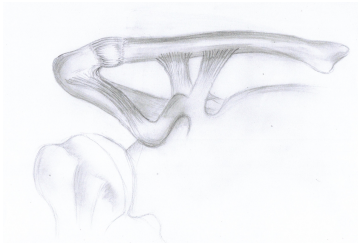


Figure 1: The anatomy

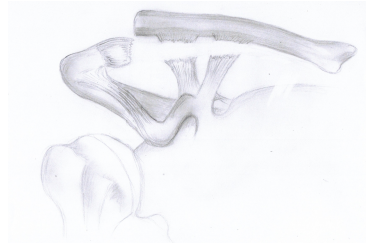


Figure 2: The lesion

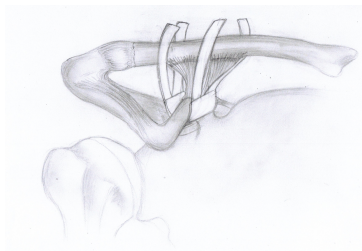


Figure 3: **The hammock**

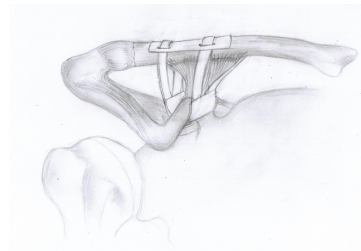


Figure 4: **The parachute**

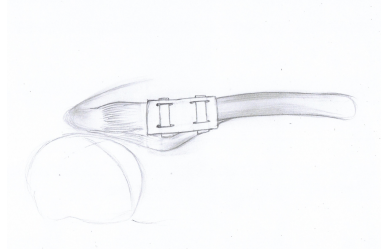


Figure 5: **The key to lock**

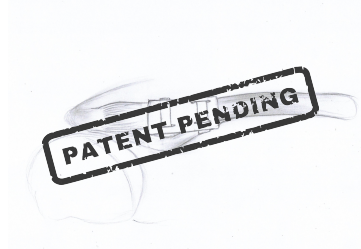


Figure 5: **The key to lock**




Figure 5: **The key to lock**

*No, thank you*