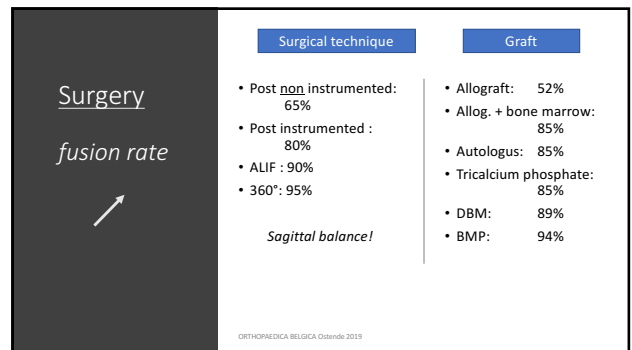
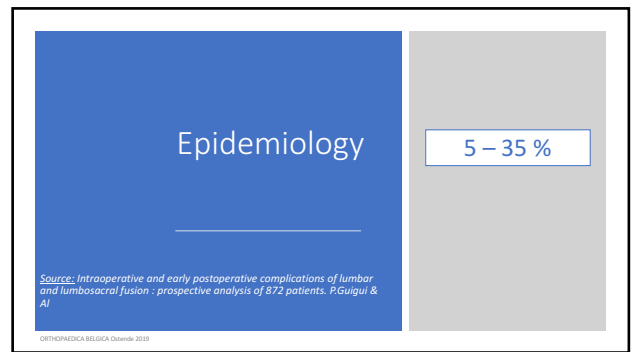
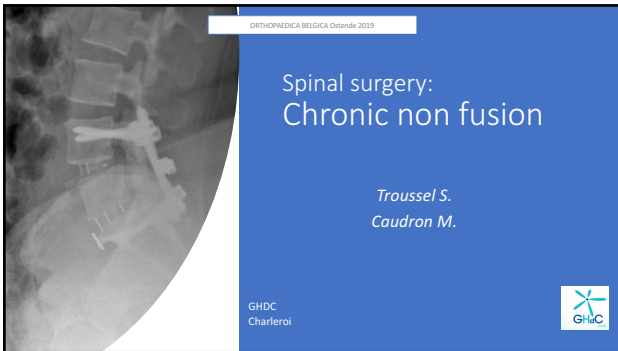Patient
fusion rate

Smoker

Previous surgery

Diabete

Comorbidities factors

ORTHOPAEDICA BELGICA Ostende 2019

DIAGNOSIS

CLINICAL HISTORY

RADIOLOGICAL FINDINGS

OTHERS

Clinical history

Radiological findings

Others

ORTHOPAEDICA BELGICA Ostende 2019

Clinical history

Good immediate postop evolution

Recurrence pain after 6 weeks

ORTHOPAEDICA BELGICA Ostende 2019

Radiological findings

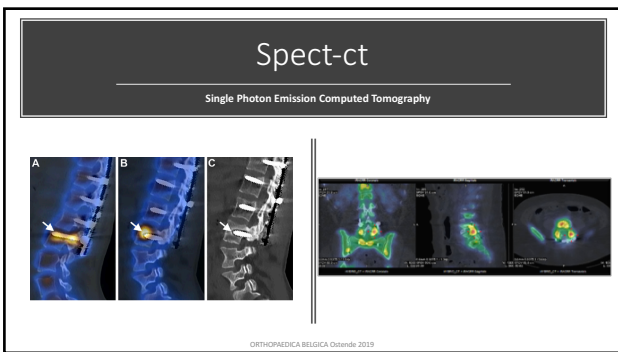
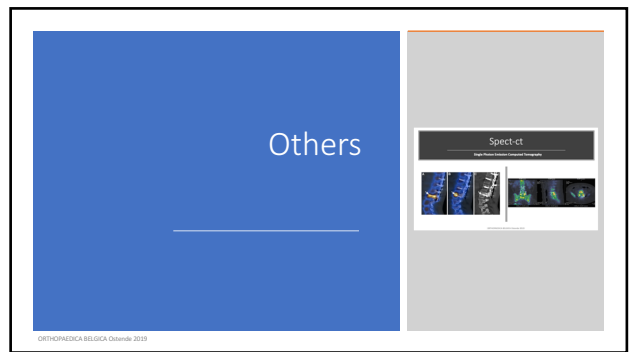

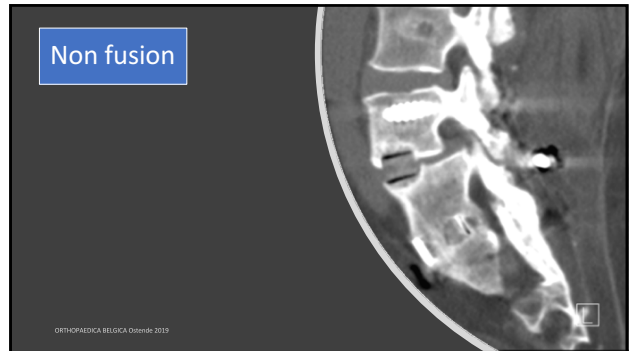
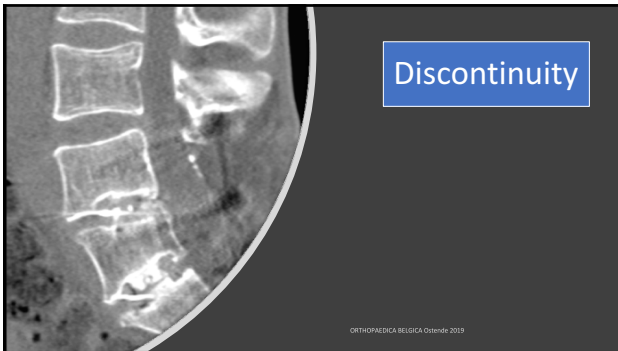
ORTHOPAEDICA BELGICA Ostende 2019

- RADIOLUCENCY
- SCREW LOOSENING
- DISCONTINUITY
- IMPLANT FAILURE
- NON FUSION
- TRANSLATION 3mm
- ANGULAR MOTION 5°

ORTHOPAEDICA BELGICA Ostende 2019

Radiolucency

ORTHOPAEDICA BELGICA Ostende 2019



Non surgical



Exercise medicine

ORTHOPAEDICA BELGICA Ostende 2019


Surgical



ORTHOPAEDICA BELGICA Ostende 2019

SURGICAL REVISION


- Larger size of the screws
(cemented if necessary)
- Posterolateral fusion, completed to 360°
- Autograft, allograft + bone marrow, BMP.



ORTHOPAEDICA BELGICA Ostende 2019

Take Home Messages

- Right patient
- Right surgery, graft !
- 360°
- Less level as possible
- Sagittal balance



ORTHOPAEDICA BELGICA Ostende 2019