

# And suddenly the stem breaks...

## Implant failure in THA

**Dr. Stijn Ghijssels**

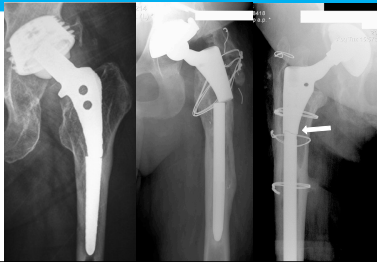Department of Orthopaedics, UZ Leuven

J. Vanbiervliet - J. Van Humbeeck - A. Braem - JP. Simon

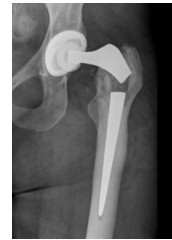Implant fractures are rare....



But can be very annoying...



The reason is not always obvious  
...and many questions will arise

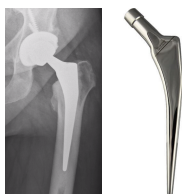


Exeter stem

## Our experience with stem fractures

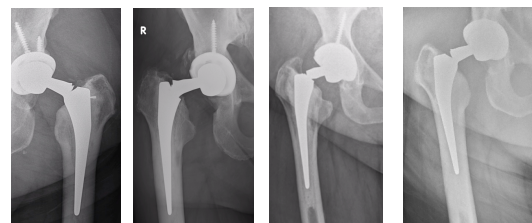
**Fortress Cemented stem** (Biotechni, France)

- Polished tapered stem
- Curved shoulder
- Ideal use for narrow canal
- 2010 - 2017

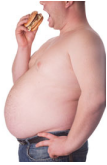

**315 THA in 275 patients**

Results **6 fractures = 2% at 5y FU**



## Risk factors

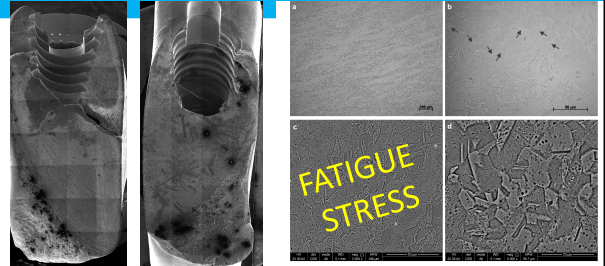


- Smallest stem sizes (8 - 9) & BMI > 33
- Patients with small stem + BMI > 30 : **5/30 broken**
  - ➔ More fractures to be expected
- No effect of NSA or head size

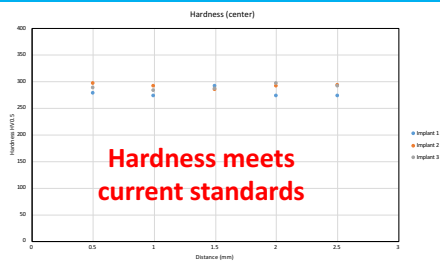### Treatment:

- Revision with cement-in-cement (5)
- Modular long stem (1)


## Reasons for failure



## Reasons for failure

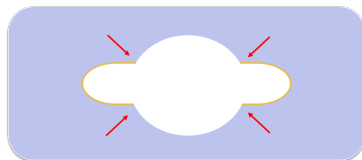


## Design Fault ?




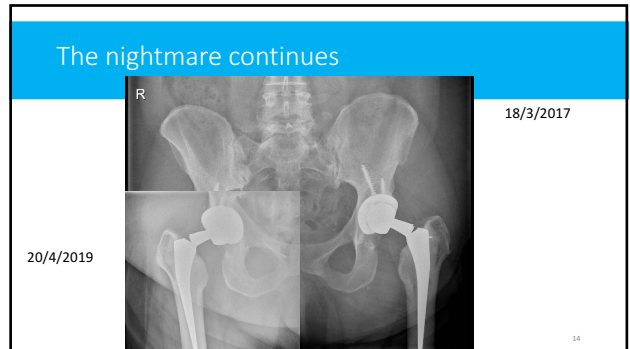
**Stress riser at introducer inlet**

## Design Fault



**SHARP vs ROUNDED corners**





NOW WHAT ?

**1 Lawsuit**     ~~309~~ <sup>308</sup> implants still in place     **Implant withdrawn**

Warn?  
 Revise?  
 At risk?  
 Extra FU / XR?  
 Costs?  
 Public reporting?

Thank you for you attention

EVENTS September, 2019

2019-09-21  
 Dual Mobility in Primary and Revision Hip Surgery

Stijn.Ghijssels@uzleuven.be