

Orthopedie Geel

DORSAL WRIST PLATING

ORTHOPAEDICA BELGICA FALL COURSE
16.11.2019 3Square Gent



Jantine Brauns
Wim Vandesande

Orthopaedic Surgery
Sint-Dimpna Hospital Geel



1


DORSAL WRIST PLATING STUDY

N = 17 patients

PARTIAL ARTICULAR FRACTURES (B type)

Group: Radius, distal end segment, partial articular, dorsal (Bartenfly) fracture 20302

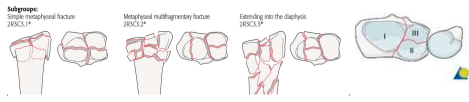
Subgroups:
 Simple fracture 20302.1
 Fragmentary fracture 20302.2
 With dorsal dislocation 20302.3



COMPLETE ARTICULAR FRACTURES (C type)


Group: Radius, distal end segment, complete articular multisegmentary fracture, simple or multisegmentary metaphyseal fracture 20303

Subgroups:
 Simple metaphyseal fracture 20303.1
 Metaphyseal multisegmentary fracture 20303.2
 Extending into the diaphysis 20303.3



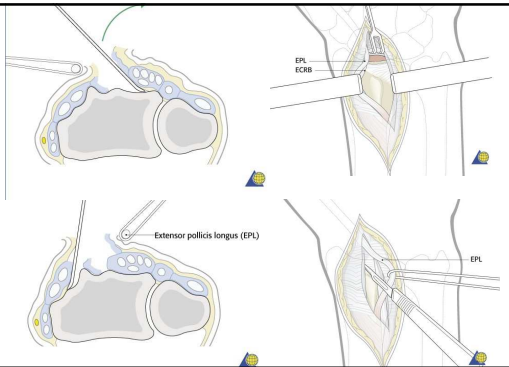
2

Case Example



Fragmentary fracture 20302.2

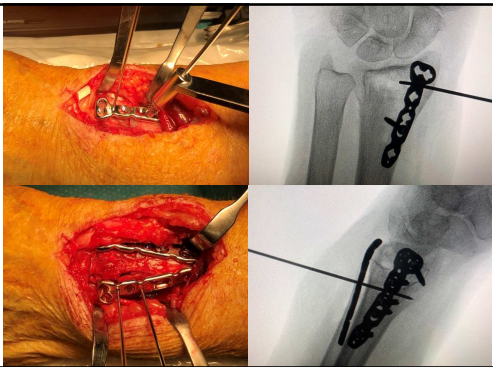
3



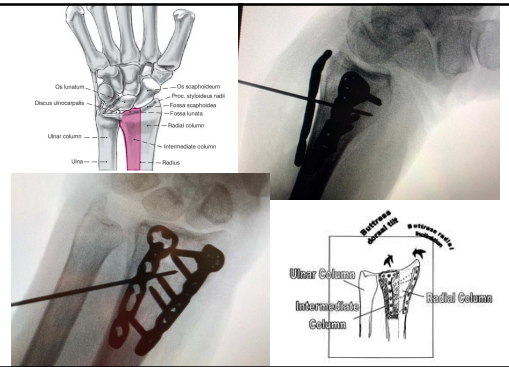
EPL
ECRB

Extensor pollicis longus (EPL)

4



5

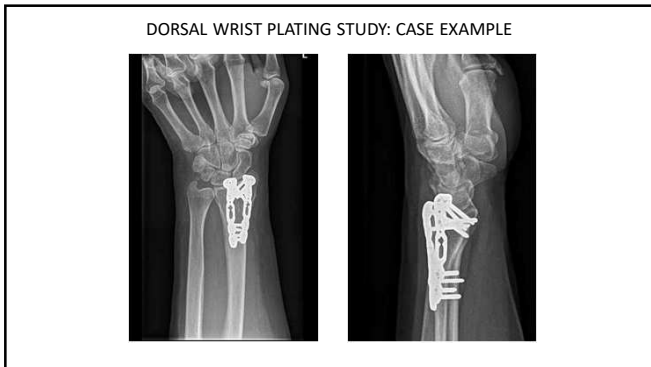

Ox lunatum
 Discus ulnocarpalis
 Ulnar column
 Ulna

Ox scaphoidum
 Pons scaphoidei
 Fossa scaphoidea
 Fossa lunate
 Radial column
 Intermediate column
 Radius

Ulnar Column
 Intermediate Column
 Radial Column

6



7

Study Results

CLINICAL OUTCOME PARAMETERS:

- Total ROM 92 % of contralateral
- Grip strength 24,5 kg vs 29,5 kg
- Key pinch 6,5 kg vs 7,4 kg

- Mayo Wrist Score (MWS): 89/100
- DASH Score: 4,4

8

Study Results

RADIOLOGICAL OUTCOME PARAMETERS:

- Articular step-off:
 - 0mm in 15 patients
 - 1 mm in 1 patient
 - 2mm in 1 patient
- Radial inclination: restored in all patients
- Radial tilt
 - anatomically restored (10-15°) in 7 patients
 - acceptably restored (0-10°) in 10 patients
- No radial shortening

COMPLICATION RATIO:

- No infections
- No tendon ruptures
- No CRPS (prevention: vitamin C)
- No mal- or Non-unions

9

Conclusion

- Direct intra-articular congruency control
- Stable reduction, early mobilization
- Anatomical restoration
- Excellent outcome
- Safe procedure: low complication ratio

10

References

- Rikli DA, Regazzoni P. Fractures of the distal end of the radius treated by internal fixation and early function. A preliminary report of 20 cases. *J. Bone Joint Surg. Br.* 1996 Jul;78(4):588-92.
- De Smet A et al. Dorsal approach and internal fixation of impacted intra-articular distal radius fractures with 2.4mm locking plates. *Hand Surg Rehab.* 2016.
- Gajados R, Bozlik M, Stranak P. Is an implant removal after dorsal plating of distal radius fracture always needed? *Brazíl Lek Lísty.* 2015; 116(6): 357-362.
- Rikli DA et al. Dorsal double plate fixation of distal radial fractures. *Eur J Trauma Emerg Surg.* 2007 Feb;33(1):99-109
- Spiteri M, NG W, Matthews J et al. Three Year Review of Dorsal Plating for Complex Intra-Articular Fractures of the Distal Radius. *J Hand Asian-Pac.* 2018; 23: 221-226
- Rhee PC, Alexander YS. Management of Complex Distal Radius Fractures: Review of Treatment Principles and Select Surgical Techniques. *The Journal of hand surgery.* 2016; 21(2): 140-154
- Peine R, Rikli DA, Hoffmann R et al. Comparison of Three Different Plating Techniques of the Distal Radius: A Biomechanical Study. *The Journal of hand surgery.*
- Yangyang R, Melvin C, Sherwin Tabrizi et al. Complications of Low-Profile Dorsal Versus Volar Locking Plates in the Distal Radius: A Comparative Study. *JHS.* 2011. 36: 1135-1141
- Hamada Y, Gotani H, Hibino N et al. Surgical Strategy and Techniques for Low-Profile Plating in Treating Dorsally Displaced Unstable Distal Radius Fractures. *J Wrist Surg.* 2017; 6: 163-169

11